

An Overview of Ocular Transmission as Alternative Route Transmission Coronavirus Disease 2019 (COVID-19): Literature Review

Ahmad Rizki Nur Hakiki¹, Siswoyo², Jon Hafan Sutawardana³, Murtaqib⁴, Rismawan Adi Yunanto⁵

¹Undergraduate Nursing Student, Faculty of Nursing, Universitas Jember, Indonesia;

ahmad.rizki33@yahoo.com (Corresponding author)

^{2,3,4,5}Department of Medical-Surgical Nursing, Faculty of Nursing, Universitas Jember, Indonesia

Article Info:

Submitted:

24-07-2022

Revised:

13-10-2022

Accepted:

20-10-2022

DOI:

<https://doi.org/10.53713/nhs.v3i1.182>

ABSTRACT

Coronavirus Disease 2019 (COVID-19) becomes a health crisis in the world. The main route of spreading COVID-19 is through the respiratory tract, but this virus also spread through the eyes. This literature review aimed to describe ocular transmission as an alternative route of COVID-19 transmission. This literature review study used sources of articles obtained through ProQuest, Springer, ScienceDirect, PubMed, and Google Scholar with a range of 2019-2020 publication years and was traced using a combination of search terms for ocular transmission, virus receptor, eye manifestation, and COVID-19. Previous research used Experimental design, Case study, and Cross-sectional study, and was published from 2019 to 2020. Then analyzed by the PRISMA diagram method with four stages starting from identification, screening, eligibility, and included. 4 articles used Experimental study design, 4 articles used Cross-sectional study design, and 2 articles used case study design. This study showed that COVID-19 RNA was found in the ocular (conjunctiva and cornea) in a low percentage (2.23%-24%). Patients with confirmed COVID-19 could have ocular manifestations, based on the report, conjunctivitis is the most common eye symptom, besides that also reported photophobia, Itchiness, Burning sensation, Gritty feeling, and Blurred vision. COVID-19 enters the human body through the eye by spike protein binds to eye receptors that are: ACE2, CD147/Basigin/EMMPRIN, TMPRSS2, ANPEP, and AGTR2. Then this virus is transferred to the respiratory tract through the nasolacrimal duct. This study showed that ocular transmission could be an alternative route of COVID-19 transmission even with a low percentage level. The nurse should act in disease prevention such as wearing an eye protector.

Keywords: ocular transmission; ocular manifestation; COVID-19



This work is licensed under CC BY-SA License.

INTRODUCTION

Coronavirus Disease 2019 (COVID-19) has become a global health crisis. COVID-19 is caused by Severe Acute Respiratory Syndrome Coronavirus 2 (SARS-CoV-2). COVID-19 has not only spread in China but has spread to more than 20 countries and has become a global health threat (Qing et al., 2020). Previous study showed that COVID-19 found in human body fluids, that are: saliva, blood, and feces (Li et al., 2020). The main transmission route is through respiratory route, but this virus can also spread through the extra-respiratory route (Sadhu et al., 2020). Ocular transmission can be a potential transmission of COVID-19 because conjunctiva can be easily contaminated with the virus through droplets and body fluids from people who are confirmed positive COVID-19 (Ho et al., 2020). Droplets contaminate the eyes through the habit of rubbing the eyes and not wearing eye protector.

The prevalence of COVID-19 on June 21, 2021, the World Health Organization (WHO) reported 178,202,610 confirmed cases of COVID-19 and 3,865,738 deaths worldwide. In Indonesia, reported on June 21, 2021, reported 2,004,445 confirmed cases of COVID-19 and 54,956 deaths. In East Java on June 21, 2021, reported 159,059 confirmed cases of COVID-19 and 11,707 deaths. In Jember Regency on June 21, 2021, reported 7,199 confirmed cases of COVID-19 and 491 deaths. Previous Study reported from 86 post-COVID-19 patients who domiciled in Kaliwates Subdistrict, Jember, there are 75 (87.2%) patients with moderate symptom and 11 (12.8%) with severe symptom (Widoati et al., 2022).

COVID-19 can be detected by reverse-transcription polymerase chain reaction (RT-PCR), Shen et al. (2020) reported the sensitivity and specificity of RT-PCR were 82.50% to 95.00%. RT-PCR tests using specimens including nasopharyngeal and oropharyngeal swabs, sputum, bronchoalveolar lavage, tracheal aspirate, nasopharyngeal aspirate, or nasal wash in viral transport medium (VTM), tissue biopsy or autopsy including from the lungs in VTM or saline media, and Serum (2 samples namely acute and convalescent) for serology (Kemenkes RI, 2020). To determine the transmission of COVID-19 through the eyes, a previous study performs an RT-PCR test using a conjunctiva swab specimen. A study in January 2020 in Wuhan reported that from 63 patients who were confirmed positive for novel coronavirus pneumonia (NCP) with conjunctival swabs, there was 1 patient positive for COVID-19 (Y. Zhou et al., 2020). In May 2020 reported from 412 confirmed COVID-19 patients by conjunctival swabs, and 12 patients (2.9%) were positive (Ho et al., 2020). Research in China reported that the percentage of confirmed COVID-19 patients with eye manifestations ranged from 2% (2 patients of 100 confirmed COVID-19) to 46% (12 patients of 26 confirmed COVID-19) (Ulhaq and Soraya, 2020). Another study reported that from 1875 (84.2%) positive COVID-19 with nasopharyngeal swabs, 95 patients (4.3%) showed eye manifestations, and 21 patients (0.9%) reported that eye manifestations were the only presenting symptom of COVID-19 (Ho et al., 2020). The American Academy of Ophthalmology reports that conjunctivitis is a symptom that appears in patients infected with COVID-19. Several studies have reported that COVID-19 can cause conjunctivitis as an early sign of infection or during treatment (Ho et al., 2020). Another study from 1099 patients found that 0.8% had conjunctiva manifestations (Hu et al., 2021). Meanwhile, Xie et al. (2020) reported that COVID-19 potentially be transmitted from normal/asymptomatic conjunctiva in patients with confirmed COVID-19 (Xie et al., 2020).

Viruses can easily contaminate conjunctiva (Qing et al., 2020). According to Zuu et al (2013) in Priscilia et al (2020), the COVID-19 virus is surrounded by an envelope consisting of a lipid bilayer and envelope protein. This virus can enter human cells after the S protein in the envelope binds to the angiotensin-converting enzyme 2 (ACE-2) cell membrane. Based on genomic and structural analysis, the study reported that COVID-19 has a receptor binding similar to SARS-CoV, which allows COVID-19 to infect the host cells by angiotensin-converting enzyme 2 (ACE-2) (Wan et al., 2020). The angiotensin-converting enzyme 2 (ACE-2) receptor is the main gateway for COVID-19 (Sahu et al., 2020). ACE2 was found in the conjunctiva at 0.26%-1% and the cornea at 0.1%. Conjunctiva also has COVID-19 receptors, namely Basigin/CD147/EMMPRIN and transmembrane serine protease 2 (TMPRSS2) (Leonardi et al., 2020). COVID-19 is present in the conjunctiva and can enter the respiratory tract through the nasolacrimal duct (Ho et al., 2020). Efforts to prevent COVID-19 transmission by using Personal Protective Equipment (PPE) such as medical masks and eye protectors, a previous study reported by 63 respondents, 47 (74.6%) respondents obediently used PPE, and 16 (25.4%) respondents did not comply with the use PPE (Nurleli et al., 2022). This literature review aimed to describe ocular transmission as an alternative route of COVID-19 transmission.

METHOD

Literature Search Strategy

This literature review study used sources of articles obtained through ProQuest, Springer, ScienceDirect, PubMed, and Google Scholar with a range of 2019-2020 publication years.

Keyword and Boolean operators (AND and OR) are used to specify or expand the literature search used, while the keywords used are as follows:

Table 1. Keyword Literature

Ocular transmissions	Virus receptors	Eye manifestations	COVID-19
Ocular transmissions	Virus receptors	Eye manifestations	Covid-19
OR			OR
Eye transmissions			SARS-CoV-2
			OR
			Coronavirus Disease 2019

These keywords are combined with a Boolean operator to become (“Ocular transmissions” OR “Eye transmissions”) AND (“Virus receptors”) AND (“Ocular manifestation”) AND (“COVID-19” OR “SARS-CoV-2” OR “Coronavirus Disease 2019”).

Research Literature Criteria

This study used the PICOS strategy, which is as follows:

Table 2. PICOS Strategy

Criteria	Inclusion	Exclusion
Population or problem	Patient confirmed positive COVID-19 based on RT-PCR test	Not patient confirmed positive COVID-19 based on RT-PCR test
Intervention	RT-PCR with swab conjunctiva specimen	RT-PCR with other than conjunctiva specimen
Comparison	There is a comparison or no comparison	No exclusion
Results	Explain the prevalence of conjunctival swabs, explain eye signs and eye symptoms in COVID-19 patients, explain ocular transmission as a transmission route for COVID-19, and explain the mechanism of COVID-19 transmission through the ocular.	Does not explain the prevalence of conjunctival swabs, does not explain eye signs and eye symptoms in COVID-19 patients, does not explain ocular transmission as a transmission route for COVID-19, and does not explain the mechanism of COVID-19 transmission through the ocular.
Research design	Experimental, Case study, Cross-sectional study	Literature review
Research Year	2019 - 2021	Before 2019
Language	English	Other than English
Index	SCOPUS	Not indexed

Literature Selection

The articles search used the PRISMA diagram method with four stages: identification, screening, eligibility, and inclusion.

1. Identification

The identification process starts with searching articles using keywords on the database used, which are: ProQuest, Springer, Science Direct, PubMed, and Google Scholar. To get specific literature, the researcher does filter settings on search engines; the settings were: setting the publication year 2019-2021, setting research articles, and setting text availability in full text. The articles found in ProQuest (n=30,412), Springer (n=114), ScienceDirect (n=18,030), PubMed (n=1,878) and Google Scholar (n=1,560)

2. Screening

The next process is screening the articles according to the theme and title; the result is 126 articles.

3. Eligibility

The next process is eligibility; eligibility is assessed based on the inclusion criteria; there are 10 articles at this stage.

4. Included

The identification, screening, and eligibility stages showed how much literature can be used in this literature review. This literature review used 10 articles.

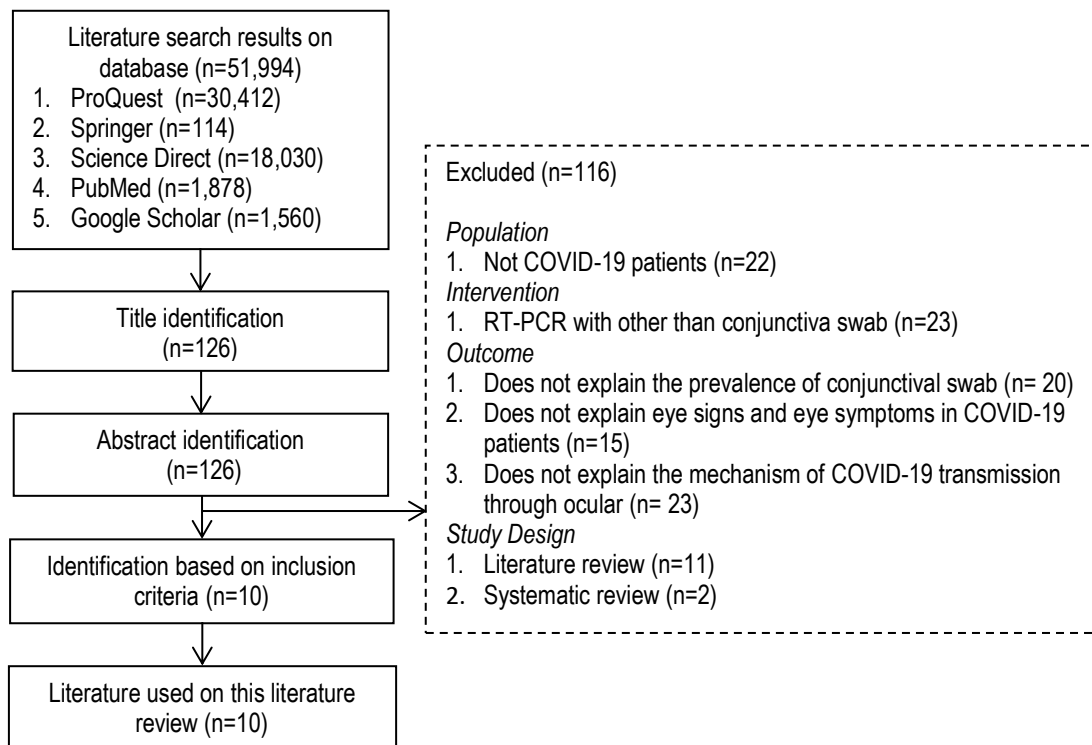


Figure 1. Literature Analysis Flow Chart Based on PRISMA

RESULT

Characteristics of the Study

Table 3. Characteristics of Literature (n=10)

Category	Number	%
Discussion		
Discussing the prevalence of COVID-19 through conjunctival swabs	3	30
Discussing eye manifestation in COVID-19 patients	4	40
Discussing the mechanism of transmission of COVID-19 through the eyes	3	30
Database		
ProQuest	0	0
Springer	1	10
ScienceDirect	2	20
PubMed	5	50
Google Scholar	2	20
Publication year		
2019	0	0
2020	10	100
2021	0	0
Study design		
Experimental	4	40
Cross-sectional study	4	40
Case study	2	20

Table 4. Literature Search Results

No	Title	Author	Publication year	Design	Population	Result	Data Base/Index
1	Evaluation of SARS-CoV-2 in Tears of Patients with Moderate to Severe COVID-19	Ritu Arora, Ruchi Goel, Sumit Kumar, Mohit Chhabra, Sonal Saxena, Vikas Manchanda, Palak Pumma	2020	Cross-sectional study	78 confirmed COVID-19 patients with moderate to severe conditions at Lok Nayak Hospital, New Delhi, India	<p>From 78 patients, 3 patients were included in the exclusion category. 36 patients (48%) with moderate condition, while 39 patients (52%) with severe condition. Out of 75 patients, a Reverse-transcription Polymerase Chain Reaction (RT-PCR) test was performed using a tear specimen, showing that 18 patients (24%) were positive for COVID-19.</p> <p>29 of the 225 samples (12.9%) of 78 patients tested positive for COVID-19, of which 11 (14.7%) used a conjunctival swab plus Schirmer's paper strip, 11 (14.7%) used a conjunctival swab, and 7 (9.3 %) sample using Schirmer's paper strip; (P = 0.3105)</p> <p>COVID-19 virus RNA was detected in 24% of confirmed COVID-19 patients with moderate to severe conditions, the criteria for moderate to severe COVID-19 patients were patients with clinical symptoms of pneumonia (fever, cough, dyspnea, rapid breathing), and no symptoms of pneumonia were found. Severe cases include an oxygen saturation of less than 94% (90%-94%), and a respiration rate of 24/min or more. While the criteria for COVID-19 patients with severe conditions are patients with clinical symptoms of pneumonia accompanied by a respiration rate of more than 30 times/minute, severe respiratory distress, oxygen saturation less than 90%.</p>	PUBMED Scopus Q1

Cont...

Cont...

No	Title	Author	Publication year	Design	Population	Result	Data Base/Index
2	Evaluation of coronavirus in tears and conjunctival secretions of patients with SARS-CoV-2 infection	Jianhua Xia, Jianping Tong, Mengyun Liu, Ye Shen, Dongyu Guo	2020	Case series study	30 patients confirmed positive for novel coronavirus pneumonia (NCP)	The study used a conjunctiva swab technique to collect specimens of tears and conjunctiva secretions, then a Reverse-transcription Polymerase Chain Reaction (RT-PCR) test was performed. From a total of 30 confirmed NCP patients (21 patients with common-type, 9 patients with severe-type) it was reported that 2 conjunctiva swab samples from common-type patients with conjunctivitis tested positive for COVID-19, and 58 conjunctiva swab samples from 20 common-type patients and 9 severe-type patients tested negative for COVID-19. Criteria for severe-type patients are (a) respiratory distress or respiratory rate 30 beats/min (b) oxygen saturation less than 93% (c) respiratory failure requiring mechanical ventilation (d) shock (e) Organ failure requiring monitoring and monitoring care in the intensive care unit.	PUBMED Scopus Q3
3	Detection of SARS-CoV-2 in conjunctival secretions from patients without ocular symptoms	Xin Li, Jasper Fuk-Woo Chan, Kenneth Kai-Wang Li, Eugene Yuk-Keung Tso, Cyril Chik-Yan Yip, Siddharth Sridhar, Tom Wai-Hin Chung, Kelvin Hei-Yeung Chiu, Derek Ling-Lung Hung, Alan Ka-Lun Wu, Sandy Ka-Yee Chau, Raymond Liu, Kwok-Cheung Lung, Anthony Raymond Tam, Vincent Chi-Chung Cheng, Kelvin Kai-Wang To, Kwok-Hung Chan, Ivan Fan-Ngai Hung, Kwok-Yung Yuen,	2020	Experimental	The study used 158 conjunctival swabs on COVID-19 patients from 49 laboratories in Hong Kong	From 158 samples, it was reported that 4 patients showed positive results of SARS-CoV-2 RNA from conjunctival swab results, using RT-PCR. Conjunctival secretions from a small proportion of asymptomatic COVID-19 patients may contain low levels of SARS-CoV-2 RNA, but the degree of transmission has yet to be determined. Appropriate infection control measures should be implemented during the ophthalmologic assessment of COVID-19 patients to prevent potential nosocomial transmission of SARS-CoV-2.	Springer Scopus Q2

Cont...

Cont...

No	Title	Author	Publication year	Design	Population	Result	Data Base/Index
4	Characteristics of Ocular Findings of Patients With Coronavirus Disease 2019 (COVID-19) in Hubei Province, China	Ping Wu, Fang Duan, Chunhua Luo, Qiang Liu, Xingguang Qu, Liang Liang, Kaili Wu	2020	Case series study	Confirmed COVID-19 patients who were admitted from February 9-15, 2020 at the central hospital of Hubei, China, were retrospectively reviewed for eye manifestations.	From 38 respondents, it was reported that 28 patients (73.7%) were positive for COVID-19 using RT-PCR from a nasopharyngeal swab, and 2 patients (5.2%) were positive for COVID-19 from a conjunctival swab. 12 of 38 patients had ocular symptoms of conjunctivitis, including conjunctival hyperemia, chemosis, epiphora or increased secretions. By univariate analysis, patients with eye symptoms were more likely to have higher white blood cells and neutrophils, and tend to have higher levels of procalcitonin, C-reactive protein, and lactate dehydrogenase than patients with confirmed COVID-19 without eye symptoms. 11 of the 12 patients with eye symptoms were confirmed positive for COVID-19 based on the RT-PCR nasopharyngeal swabs test, and 2 of them were confirmed positive based on the RT-PCR test with nasopharyngeal swabs and conjunctival swabs specimens.	PUBMED Scopus Q1
5	Ocular Manifestations and Clinical Characteristics of Children With Laboratory-Confirmed COVID-19 in Wuhan, China	Nan Ma, Ping Li, Xinghua Wang, Yueqi Yu, Xuan Tan, Peng Chen, Shilian Li, Fagang Jiang	2020	cross-sectional study	The study used 216 children patients who were confirmed positive for COVID-19 at the Wuhan Children's Hospital	from 216 COVID-19 patients, it was reported that 49 (22.7%) children showed eye symptoms, of which 9 had eye complaints as an early manifestation of COVID-19. It was reported that conjunctiva discharge was the most common manifestation, namely 27 (55.1%) children, rubbing eyes 19 (38.8%) children, conjunctiva congestion 5 (10.2%) children.	Google Scholar Scopus Q 1

Cont...

Cont...

No	Title	Author	Publication year	Design	Population	Result	Data Base/Index
6	The evidence of SARS-CoV-2 infection on ocular surface	Xian Zhang, Xuhui Chen, Liwen Chen, Chaohua Deng, Xiaojing Zou, Weiyong Liu, Huimin Yu, Bo Chen, Xufang Sun	2020	cross-sectional study	The study used 102 patients with clinical symptoms, and 72 patients confirmed positive by the SARS-CoV-2 RT-PCR test.	From 72 patients, 2 patients (2.72%) had conjunctivitis. 1 of the 2 patients found SARS-CoV-2 RNA fragments using the RT-PCR test.	Science Direct Scopus Q 1
7	Presence of viral RNA of SARS-CoV-2 in conjunctival swab specimens of COVID-19 patients	Kiran Kumar Akshata A Prakash Suresh Babu Gangasagara Sujatha Rathod BL K Ravi Ambica Rangaiah Sathyanarayan Muthur Shankar Shantala Gowdara Basawarajappa Shashi Bhushan Neeraja, Srinivas Khandenahalli, M Swetha, Priyam Gupta, U C Sampritha, Guru N S Prasad, Chakravarthy Raghunathan Jayanthi	2020	Experimental	The study involved 45 COVID-19 patients based on reverse transcription-polymerase chain reaction (RT-PCR) nasopharyngeal swab with or without ocular manifestations.	From 45 patients, no one of the patients had ocular symptoms. 1 (2.23%) of the 45 patients showed positive conjunctival swab results for SARS CoV 2.	PUBMED Scopus Q3
8	Ocular Surface Expression of SARS-CoV-2 Receptors	Andrea Leonardi Umberto Rosani & Paola Brun	2020	cross-sectional study	The study used conjunctival cell samples from 18 healthy respondents (aged 6-30 years) and 6 ex-vivo corneas from healthy donors (aged 64-72 years).	Studies reported that ACE2 was found in conjunctival samples (0.26-1%), and ACE2 was found in corneal samples in 0.1%. Whereas Basigin/CD147/EMMPRIN (BSG) was found to be moderately high (5%-9%) and transmembrane serine protease 2 (TMPRSS2) was highly expressed in the conjunctiva and cornea (0.5%-30%). Other receptors such as Aminopeptidase N (ANPEP) were found in the conjunctiva in moderate amounts (more than 3%) and angiotensin II receptor type 2 (AGTR2) was found in low levels in the conjunctiva and cornea. The 2 RNA editing enzymes APOBEC3A were found in high levels (13%-198%), and ADAR-1 was more abundant in the cornea (approx. 3.6%). BSG, TMPRSS2, ANPEP and AGTR2 have an important role in the process of entering the SARS-CoV-2 virus into the human body. In this case the researchers concluded that the ocular surface (conjunctiva and cornea) could be the entry point for SARS-CoV-2 into human body.	PUBMED Scopus Q2

Cont...

Cont...

No	Title	Author	Publication year	Design	Population	Result	Data Base/Index
9	A pneumonia outbreak associated with a new coronavirus of probable bat origin	Peng Zhou Xing-Lou Yang Xian-Guang Wang Ben Hu Lei Zhang Wei Zhang Hao-Rui Si Yan Zhu Bei Li Chao-Lin Huang Hui-Dong Chen Jing Chen Yun Luo Hua Guo Ren-Di Jiang Mei-Qin Liu Ying Chen Xu-Rui Shen Xi Wang Xiao-Shuang Zheng Kai Zhao Quan-Jiao Chen Fei Deng Lin-Lin Liu Bing Yan Fa-Xian Zhan Yan-Yi Wang Geng-Fu Xiao1 & Zheng-Li Shi	2020	experimental	The study involved 7 patients with severe pneumonia	Researchers conducted a virus infectivity study using HeLa cells expressed and not expressed with angiotensin-converting enzyme 2 (ACE2) protein from humans, Chinese bats, civets, pigs, and mice. Researchers report the results that the COVID-19 virus can use all ACE2 as receptors, except for ACE2 in mice. This indicates that ACE2 is the receptor of the COVID-19 virus in humans. Researchers confirmed that COVID-19 uses the same entry cell as the SARS-CoV virus, namely angiotensin-converting enzyme 2 (ACE2).	Google scholar Scopus Q1
10	ACE2 and TMPRSS2 are expressed on the human ocular surface, suggesting susceptibility to SARS-CoV-2 infection	Lingli Zhou Zhenhu Xu Gianni M. Castiglione, Uri S. Soiberman, Charles G. Eberhart, Elia J. Duh	2020	Experimental	The study used corneal epithelial samples obtained from healthy nearsighted patients undergoing photorefractive keratectomy for the treatment of mild to moderate myopia or myopic astigmatism	From immunohistochemistry analysis showed ACE2 expression in the conjunctiva, limbus, and cornea with very prominent staining in the superficial conjunctiva and corneal epithelial surface. Conjunctiva specimens also showed ACE2 expression in the conjunctiva epithelium, especially prominent in the superficial epithelium, as well as weak or focal expression in the substantia. All eye and conjunctiva specimens also expressed TMPRSS2.	ScienceDirect Scopus Q1

DISCUSSION

COVID-19 Prevalence Based on Conjunctiva Swab

COVID-19 cases continue to increase in the world, the global pandemic began in Wuhan, China, in December 2019, then quickly spread and spread throughout the world. On June 21, 2021, 178,202,610 confirmed cases of COVID-19 were reported in the world (WHO, 2021), while in Indonesia on June 21, 2021, there were 2,004,445 confirmed cases of COVID-19 (Covid-19 Task Force, 2021). The main route of transmission of COVID-19 is through the respiratory tract, through droplets, and through contact with surfaces contaminated with COVID-19, this virus can also spread through the extra respiratory route (Sadhu et al., 2020). Transmission of COVID-19 through the respiratory route is the main focus of handling this virus, transmission of the extra respiratory route is also important to note so that the spread of COVID-19 can be controlled.

Based on 10 articles that have been reviewed reporting the COVID-19 virus in the eye based on the RT-PCR test using tissue or eye fluid specimens, which are as follows.

Table 5. Prevalence of COVID-19 on Eyes

No	COVID-19 on eye	Place	Source
1	2 samples COVID-19 positive based on conjunctiva swab	First Affiliated Hospital of Zhejiang University, Tiongkok	(Xia et al., 2020)
2	4 cases or 8.2%	Hong Kong	(Li et al., 2020)
3	18 cases or 24%	India	(Arora et al., 2020)

The study showed that the findings of the COVID-19 virus in the eye were varied, but the incidence rate is relatively low overall. Kumar et al. (2020) reported the same thing; it was reported that there were 1 (2.23%) cases of COVID-19 RNA findings in the eyes at a South Indian Hospital. Research by Wu et al. (2020) also reported the same thing, it was reported that there were 2 (5.2%) cases of COVID-19 RNA findings in the eyes at Yichang Central People's Hospital, China. The two studies also reported a low prevalence of COVID-9 RNA findings in eyes.

COVID-19 RNA in eyes was not found in all confirmed COVID-19 patients. Arora et al. (2020) reported that COVID-19 virus RNA was detected in 24% of confirmed COVID-19 patients with moderate to severe conditions, the criteria for COVID-19 patients with moderate conditions were patients with clinical symptoms of pneumonia (fever, cough, dyspnea, rapid breathing). There were no signs of severe pneumonia including oxygen saturation less than 94% (90%-94%), and a respiration rate of 24/min or more. While the criteria for COVID-19 patients with severe conditions are patients with clinical symptoms of pneumonia accompanied by a respiration rate of more than 30 times/minute, severe respiratory distress, and oxygen saturation of less than 90%. Another study also reported the same thing from 30 patients where 2 conjunctiva swab samples from patients with a moderate condition accompanied by conjunctivitis tested positive for COVID-19 (Xia et al., 2020).

The studies show that the prevalence of COVID-19 findings in the eye is relatively low, but this is an important concern, especially for nurses and other health workers. Preventive measures are necessary for the community, especially health workers, to prevent the transmission of COVID-19 through the eyes. Qing et al. (2020) also recommend that health workers wear safety glasses when in contact with suspected and confirmed COVID-19 patients (Goggles). This is one of the steps to prevent the spread of COVID-19 through the eyes. Compared with SARS-CoV and MERS-CoV, COVID-19 is reported to have a low fatality rate. Still, previous studies reported that the number of cases of COVID-19 sufferers was almost 10 times that in the first two months of the total SARS patients (Priscilia et al., 2020); this shows that the COVID-19 virus has a very fast and widespread transmission rate. The Indonesian Kemenkes RI (2021) reports that in 2021 the COVID-19 virus with a new variant entered Indonesia; the new COVID-19 variants include B.117 from England, B.1351 from South Africa, and a double-mutated variant from India B. 1617. variant B.117 has a higher transmission rate of 75% compared to the previous virus type. Therefore, the finding of COVID-19 virus RNA in other body organ systems, including the eyes, should not be ignored because it may represent an alternative mode of transmission of COVID-19.

Eye Manifestations in COVID-19 Patients

Since December 2019 in Wuhan, China, there have been reports of eye manifestations in patients infected COVID-19 (Daruich et al., 2020). Based on the literature that has been reviewed, there are findings of COVID-19 patients with eye symptoms. Research conducted by Zhang et al. (2020) reported that out of 72 patients, 2 patients (2.72%) had conjunctivitis. 1 of the 2 patients found SARS-CoV-2 RNA fragments using the RT-PCR test. Research by Wu et al. (2020) also reported the same thing, in confirmed COVID-19 patients who were treated from February 9-15, 2020, at the central hospital of Hubei, China, retrospectively reviewed to see eye manifestations, the results showed that 12 of 38 patients experienced ocular symptoms of conjunctivitis, including conjunctiva hyperemia, chemosis, epiphora or increased secretions. Ceran & Ozates (2020) also reported similar findings, a study involving 59 confirmed COVID-19 patients at Kars Harakani State Hospital, Kars, Turkey reported the following.

Table 6. Ocular Manifestations

Manifestations	f (%)
Ocular findings	
Hyperemia	20 (21.5%)
Epiphora	9 (9.7%)
Increased secretion	6 (6.5%)
Chemosis	3 (3.2%)
Episcleritis	2 (2.2%)
Follicular conjunctivitis	8 (8.6%)
Ocular symptoms	
Photophobia	15 (16.1%)
Itchiness	13 (15.7%)
Burning sensation	7 (8.4%)
Gritty feeling	5 (6.0%)
Blurred vision	4 (4.8%)

The report showed that hyperemia, or dilation of blood vessels from the fornix to the limbus, has the highest percentage (21.5%), and photophobia has the highest percentage (16.1%). No studies have reported COVID-19 patients experiencing blurred vision, sub-conjunctiva hemorrhage, eyelid ecchymosis, conjunctiva scarring, keratitis, or pseudomembrane formation (Hu et al., 2021).

Based on the report, conjunctivitis is the most common eye symptom; conjunctivitis or pink eye is an ocular symptom that can occur in patients with confirmed COVID-19. Symptoms of conjunctivitis in COVID-19 patients can occur due to two mechanisms. First, transmitting the virus through the ocular mucosa, cornea, and conjunctiva causes red eyes. The second mechanism is a systemic viral reaction in patients with confirmed COVID-19 manifesting in the eyes as conjunctivitis (Belser et al., 2013; Wu et al., 2020).

Adult patients do not only experience eye symptoms COVID-19 patients, but pediatric patients also experience eye symptoms; the study reported that from 216 pediatric patients with confirmed COVID-19, it was reported that 49 (22.7%) children showed eye symptoms, conjunctiva discharge is the most frequent manifestation where 27 (55.1%) children, rubbing eyes 19 (38.8%) children, conjunctiva congestion 5 (10.2%) children (Ma et al., 2020).

Chen et al. (2020) reported a patient with confirmed COVID-19 based on a nasopharyngeal swab; the patient experienced red eyes and foreign body sensation in his eyes on the 6th day of treatment, on the 8th day (13th sick day) of treatment on the patient experienced watery eyes without decreased vision (Chen et al., 2020). On the other hand, research by Ma et al. (2020) reported that in 9 out of 216 confirmed patients with COVID-19, eye manifestations were early symptoms of COVID-19 infection. Patients with eye symptoms are likelier to have higher white blood cells and neutrophils. They tend to have higher levels of procalcitonin, C-reactive protein, and lactate dehydrogenase than patients with confirmed COVID-19 without eye symptoms (Wu et al., 2020). Based on these reports, patients who show eye symptoms require further examination. Eye symptoms can also be an indicator or early symptom of a patient infected with COVID-19.

On the other side, Kumar et al. (2020) reported the opposite finding, this study conducted in India reported that of 45 patients, none experienced ocular symptoms. Zhou et al. (2020) also reported the same thing; from 67 COVID-19 patients, there were no patients who experienced eye symptoms. Based on research indicates that COVID-19 patients can experience ocular symptoms or not be accompanied by eye symptoms. Still, on the other hand, eye symptoms can also be an early symptom of COVID-19 infection.

Mechanism of COVID-19 transmission through ocular

Based on virological and epidemiological studies, it has been proven that COVID-19 can be transmitted through droplets from people with symptoms (symptomatic) to other people who are close to it. Droplets are water-filled particles that have a diameter of >5-10 m; droplets can be transmitted when a person is at a close distance of one meter from a person who has respiratory symptoms such as coughing or sneezing so that droplets can hit the mucosa (nose and mouth) or conjunctiva (eye). Transmission can also occur through the surface of objects contaminated with droplets (Kemenkes RI, 2020). Research by Doremalen et al. (2020) reported that COVID-19 could survive for 72 hours on stainless steel and plastic surfaces, less than 4 hours on copper surfaces, and 24 hours on cardboard surfaces. The ability of COVID-19 to survive on the surface of objects can increase the incidence of virus transmission.

Although the risk of transmitting COVID-19 through the eyes is low, it cannot be excluded that COVID-19 uses the surface of the eye as an alternative route of entry into the human body (Leonardi et al., 2020). The ocular surface can be easily exposed to infectious droplets during close contact with infected individuals and contaminated hands; this

allows the ocular surface to have a role as a virus entry point, reservoir for virus replication, and transmission of the COVID-19 virus (Arora et al., 2020; Qing et al., 2020). Droplets can enter the eyes through the habit of wiping the eyes without paying attention to hand hygiene and not using eye protection; eye protection needs to be worn as a preventive measure for COVID-19 transmission through airborne. Research Doremalen et al. (2020) reported that COVID-19 could survive in the air for more than 1 hour. With the ability of COVID-19 to live in the air, there is a possibility that COVID-19 can enter the human eye through the air.

COVID-19 is surrounded by an envelope consisting of a lipid bilayer and an envelope protein. There are 4 main protein structures in Coronavirus, namely: protein N (nucleocapsid), glycoprotein M (membrane), glycoprotein spike S (spike), and protein E (sheath) (Ministry of Health RI, 2020). COVID-19 enters human cells through the S protein on the viral envelope binding to the cell membrane receptor, namely angiotensin-converting enzyme 2 (ACE2) (Priscilia et al., 2020). ACE2 is a receptor widely found in the human body, one of which is in the eye. Then proteolytic enzymes break down protein S into S1 and S2, which are assumed to be furin. The S1 protein binds to the ACE2 receptor. And another fragment, S2, is divided by transmembrane protease serine 2 (TMPRSS2), TMPRSS2 is a serine protease that is an activator of spike glycoprotein (S protein) after protein S is cleaved by TMPRSS2, protein S can bind to cell surface receptors (Zhu et al., 2013; Barnett et al., 2020).

Zhou et al. (2020) reported findings of COVID-19 receptors in the eye based on a viral infectivity study using HeLa cells overexpressed and unexpressed with the angiotensin-converting enzyme 2 (ACE2) protein from humans, Chinese bats, civets, pigs, and mice. The study reported that the COVID-19 virus can use all ACE2 as receptors, except for ACE2 in mice. This indicates that ACE2 is the receptor of the COVID-19 virus in humans. Researchers confirmed that COVID-19 uses the same entry cell as the SARS-CoV virus, namely angiotensin-converting enzyme 2 (ACE2). Another study also reported the same thing; of all specimens, Immunohistochemical analysis showed ACE2 expression in the conjunctiva, limbus, and cornea with very prominent staining on the superficial conjunctiva and the surface of the corneal epithelium. Conjunctiva specimens also showed ACE2 expression in the conjunctiva epithelium, especially prominent in the superficial epithelium, and weak or focal expression in the substantial (L. Zhou et al., 2020). These two reports confirm that ACE2 in humans is a COVID-19 receptor and that ACE2 is also found in the human conjunctiva.

ACE2 is not the only COVID-19 receptor present in the human eye, Leonardi et al. (2020) reported the finding of COVID-19 receptors in the eye, ACE2 was found in conjunctiva samples by 0.26-1%, and ACE2 was found in corneal samples by 0.1%. Meanwhile, Basigin/CD147/EMMPRIN (BSG) was found in quite high amounts, namely 5%-9%, and transmembrane serine protease 2 (TMPRSS2) was expressed quite high in the conjunctiva and cornea (0.5% - 30%). Other receptors, such as Aminopeptidase N (ANPEP), were found in the conjunctiva in moderate amounts (more than 3%), and angiotensin II receptor type 2 (AGTR2) was found in low levels in the conjunctiva and cornea. The 2 RNA editing enzymes APOBEC3A were found in high levels (13%-198%), and ADAR-1 was more abundant in the cornea (approximately 3.6%). Angiotensin-converting enzyme 2 (ACE2) is the COVID-19 binding receptor. ACE2 is highly expressed in human lung alveolar epithelial cells, small intestinal enterocytes, and renal proximal tubular cells, ACE2 expression in human conjunctiva and corneal epithelial cells is much less than in lung and kidney tissue and has protein binding ability. ACE2 of conjunctiva epithelial cells with COVID-19 spike protein was much lower than that of lung tissue (Priscilia et al., 2020). CD147, known as Basigin or extracellular matrix metalloproteinase inducer (EMMPRIN), was also identified as red blood cell (RBC) Plasmodium falciparum – the protozoan that causes malaria in humans, CD147 is also the receptor for the COVID-19 spike protein (Ulrich and Pillat, 2020). Aminopeptidase N (ANPEP) and angiotensin II receptor type 2 (AGTR2) are also COVID-19 receptors (Leonardi et al., 2020). The finding of COVID-19 spike protein binding receptors in the eye indicates the eye could be an alternative pathway for COVID-19.

The COVID-19 receptors in the eyes are the main key for this virus to enter the eyes; the COVID-19 virus can be in the eyes through droplets of COVID-19 patients hitting the eye area, rubbing the eyes without paying attention to hand hygiene, and transmission of the COVID-19 virus via aerosol. Then the virus will be transferred to the respiratory tract. Belser et al. (2013) explained the theory for the transmission of respiratory diseases through the eyes by passing through the nasolacrimal system; they proposed that the ocular mucosal immune system consisting of the conjunctiva, cornea, lacrimal gland, and lacrimal drainage system will clean fluid from the eye and send it to the inferior meatus of the nose, if the eye contaminated with the virus, the virus will be carried to the respiratory system through the nose, and will be carried to the lungs. Respiratory syncytial virus (RSV) is a respiratory system disease that has been demonstrated to spread through the eyes and into the nose. The eye is a receptor associated with a viral binding in RSV, and eye protection has been shown to reduce nosocomial transmission of RSV. This theory is supported by studies that have found viral load in the tears of patients with respiratory disease; this theory has been studied in animal models, including rats, ferrets, rabbits, and cotton rats. After inoculating detectable viral loads in tear samples from all animals, all these animals also had clinical symptoms of respiratory viral infection comparable to traditional intranasal inoculation. The same study was carried out on feline coronaviruses. In a study of feline CoV-positive cats, 90% had antigens found on

the conjunctiva after a conjunctival swab. The same thing also happened to the COVID-19 virus; several studies reported the presence of COVID-19 virus receptors in the human eye, and the findings of COVID-19 RNA in the human eye; this can be a basic theory that the eye can be an alternative entry point for COVID-19 into the human eye.

CONCLUSION

COVID-19 was found in the ocular (conjunctiva and cornea), although in a low percentage. COVID-19 patients may have ocular symptoms or no ocular symptoms. Reported ocular symptoms include conjunctivitis, conjunctival hyperemia, chemosis, epiphora, or increased secretions. COVID-19 can enter the human body through the eyes by spike protein (protein S) COVID-19 binds to eye receptors, then transferred to the respiratory tract through the nasolacrimal duct; in this case, ocular transmission can be an alternative route of transmission of the COVID-19 virus. The nurse needs to pay attention to this COVID transmission route. The nurse must use an eye protector during the caring process.

REFERENCES

- Arora, R., Goel, R., Kumar, S., Chhabra, M., Saxena, S., Manchanda, V., & Pumma, P. (2020). Evaluation of sars-cov-2 in tears of patients with moderate to severe covid-19. *Ophthalmology*
- Barnett, B. P., Wahlin, K., Krawczyk, M., Spencer, D., Welsbie, D., Afshari, N., & Chao, D. (2020). Potential of ocular transmission of sars-cov-2: a review. *Vision (Switzerland)*, 4(3), 1–14.
- Belser, J. A., Rota, P. A., & Tumpey, T. M. (2013). Ocular tropism of respiratory viruses. *Microbiology and Molecular Biology Reviews*, 77(1), 144–156.
- Chen, L., Liu, M., Zhang, Z., Qiao, K., Huang, T., Chen, M., Xin, N., Huang, Z., Liu, L., Zhang, G., & Wang, J. (2020). Ocular manifestations of a hospitalised patient with confirmed 2019 novel coronavirus disease. *British Journal of Ophthalmology*. (figure 2), 748–751.
- Daruich, A., Martin, D., & Bremond-Gignac, D. (2020). Ocular manifestation as first sign of coronavirus disease 2019 (covid-19): interest of telemedicine during the pandemic context. *Journal Francais d'Ophtalmologie*, 43(5), 389–391.
- Ho, D., Low, R., Tong, L., Gupta, V., Veeraraghavan, A., & Agrawal, R. (2020). COVID-19 and the ocular surface: a review of transmission and manifestations. *Ocular Immunology and Inflammation*, 28(5), 726–734.
- Hu, K., Patel, J., & Patel, B. (2021). *Ophthalmic Manifestations Of Coronavirus (COVID-19)*. StatPearls Publishing LLC.
- Kemendes RI. (2020). *Pedoman Pencegahan Dan Pengendalian Coronavirus Disease (COVID-19)*. Jakarta.
- Kumar, K., Prakash, S. B. G. A. A., Rathod BL, K. R. S., Rangaiah, S. M. S. A., Basawarajappa, S. G., Shashi Bhushan, C. R. J., Neeraja, T. G., Srinivas Khandenahalli, Swetha, M., Priyam Gupta, Sampritha, U. C., & Prasad, G. N. S. (2020). Presence of viral rna of sars-cov-2 in conjunctival swab specimens of covid-19 patients. *Indian Journal of Ophthalmology*
- Leonardi, A., Rosani, U., & Brun, P. (2020). Ocular surface expression of sars-cov-2 receptors. *Ocular Immunology and Inflammation*, 28(5), 735–738.
- Li, X., Fuk, J., Chan, W., Kai, K., Li, W., Yuk, E., Tso, K., Chik, C., Yip, Y., Sridhar, S., Wai, T., Chung, H., Hei, K., Chiu, Y., Ling, D., & Hung, L. (2020). Detection of sars - cov - 2 in conjunctival secretions from patients without ocular symptoms. *Infection*. (0123456789)
- Lihua, S., Fei, H., Chen, X., Zuan, X., Yang, X., Li, H., Cheng, F., Guo, J., & Gong, G. (2020). Diagnostic efficacy of three test kits for sars-cov-2 nucleic acid detection. *Journal of Zhejiang University*, 49(2).
- Ma, N., Li, P., Wang, X., Yu, Y., Tan, X., Chen, P., Li, S., & Jiang, F. (2020). Ocular manifestations and clinical characteristics of children with laboratory-confirmed covid-19 in wuhan, china. *JAMA Ophthalmology*, 138(10), 1079–1086.
- Nurleli, Kundaryanti, R., & Novelia, S. (2022). The Use of Personal Protective Equipment Compliance among Midwives During COVID-19 Pandemic in Indonesia. *Nursing and Health Sciences Journal*, 2(2), 111-123.
- Priscilia, F., Iskandar, F., Larasati, F. F., & Permanik, G. F. (2020). Manifestasi okular coronavirus disease 2019 (covid-19): klinis dan pencegahan. 47(8), 667–672.
- Qing, H., Li, Z., Yang, Z., Shi, M., Huang, Z., Song, J., & Song, Z. (2020). The possibility of covid-19 transmission from eye to nose. *Acta Ophthalmologica*, 98(3), e388.
- Sadhu, S., Agrawal, R., Pyare, R., Pavesio, C., Zierhut, M., Khatri, A., Smith, J. R., de Smet, M. D., & Biswas, J. (2020). COVID-19: limiting the risks for eye care professionals. *Ocular Immunology and Inflammation*, 28(5), 714–720.
- Sahu, D. K., Pradhan, D., Naik, P. K., Kar, B., Ghosh, G., & Rath, G. (2020). Smart polymeric eye gear: a possible preventive measure against ocular transmission of covid-19. *Medical Hypotheses*, 144(June), 110288.
- Satgas COVID-19. (2021). *Situasi Virus COVID Di Indonesia*. <https://covid19.go.id/>
- Ulhaq, Z. S., & Soraya, G. V. (2020). The prevalence of ophthalmic manifestations in covid-19 and the diagnostic value of ocular tissue/fluid. *Graefe's Archive for Clinical and Experimental Ophthalmology*, 258(6), 1351–1352.
- Ulrich, H., & Pillat, M. M. (2020). CD147 as a target for covid-19 treatment: suggested effects of azithromycin and stem cell engagement. *Stem Cell Reviews and Reports*, 16(3), 434–440.
- Wan, Y., Shang, J., Graham, R., Baric, R. S., & Li, F. (2020). Receptor recognition by the novel coronavirus from wuhan: an analysis

- based on decade-long structural studies of sars coronavirus. *Journal of Virology*, 94(7), 1–9.
- Widowati, S. A., Dewi, E. I., Kurniyawan, E. H., Sutawardana, J. H., & Fitria, Y. (2022). Description of Self Stigma Incidence in Post COVID-19 Patients. *Nursing and Health Sciences Journal*, 2(3), 215-223.
- WHO. (2021). *WHO Coronavirus (COVID-19) Dashboard*. <https://covid19.who.int/>
- Wu, P., Duan, F., Luo, C., Liu, Q., Qu, X., Liang, L., & Wu, K. (2020). Characteristics of ocular findings of patients with coronavirus disease 2019 (covid-19) in hubei province, china. *JAMA Ophthalmology*, 138(5), 575–578.
- Xia, J., Tong, J., Liu, M., Shen, Y., & Guo, D. (2020). Evaluation of coronavirus in tears and conjunctival secretions of patients with sars-cov-2 infection. *Journal of Medical Virology*, 92(6), 589–594.
- Xie, H.-T., Jiang, S.-Y., Xu, K.-K., Liu, X., Xu, B., Wang, L., & Zhang, M.-C. (2020). SARS-cov-2 in the ocular surface of covid-19 patients. *Eye and Vision*, 7(1), 7–9.
- Zhang, X., Chen, X., Chen, L., Deng, C., Zou, X., Liu, W., Yu, H., Chen, B., & Sun, X. (2020). The evidence of sars-cov-2 infection on ocular surface. *Ocular Surface*, 18(3), 360–362.
- Zhou, L., Xu, Z., Castiglione, G. M., Soiberman, U. S., Eberhart, C. G., & Duh, E. J. (2020). ACE2 and tmprss2 are expressed on the human ocular surface, suggesting susceptibility to sars-cov-2 infection. *Ocular Surface*, 18(4), 537–544.
- Zhou, Y., Zeng, Y., Tong, Y., & Chen, C. (2020). Ophthalmologic evidence against the interpersonal transmission of 2019 novel coronavirus through conjunctiva. *MedRxiv*.
- Zhu, X., Liu, Q., Du, L., Lu, L., & Jiang, S. (2013). Receptor-binding domain as a target for developing sars vaccines. *Journal of Thoracic Disease*, 5(SUPPL.2).